



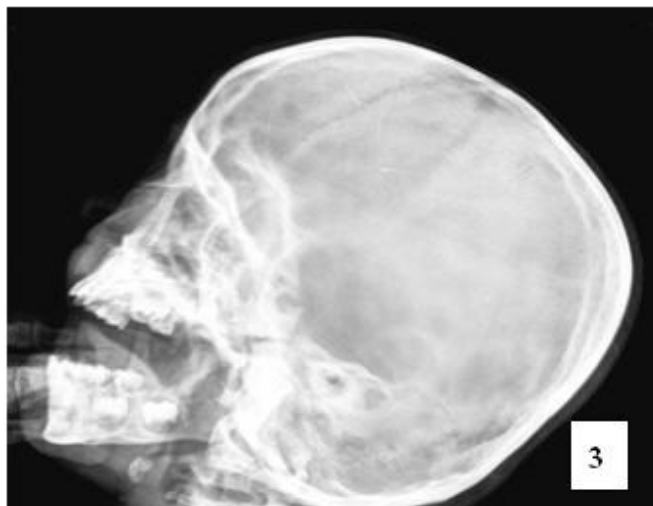
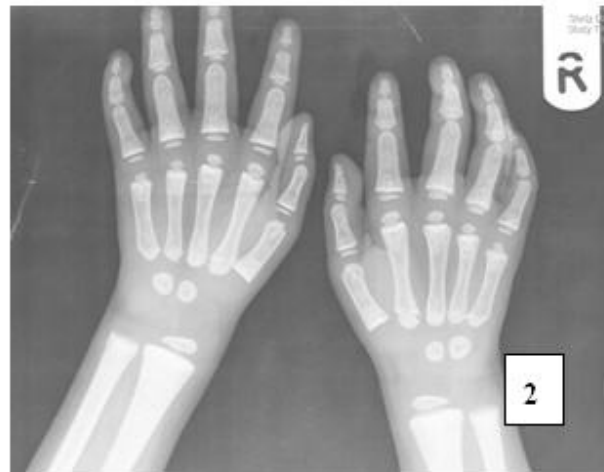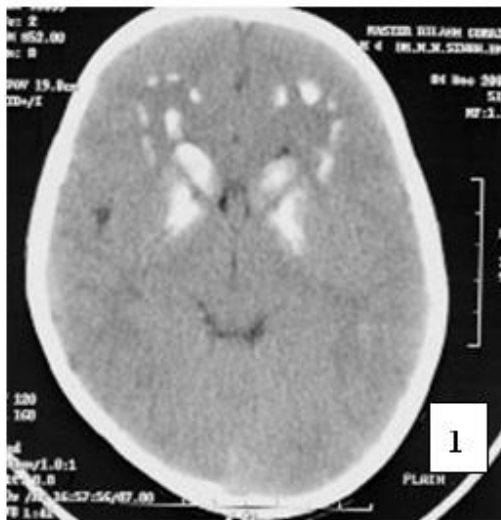Dense bones and brain stones

Suresh Prabhu, Jubbin J Jacob, Nihal Thomas

A 4-year-old boy presented with delay in developmental milestones and aggressive behaviour. An axial CT scan of the brain was done (Figure 1).

Subsequent evaluation revealed normal serum calcium and inorganic phosphorus values with an elevated serum alkaline phosphatase. His arterial blood gas analysis was suggestive of metabolic acidosis with anionic gap of minus 15.1.

His skeletal X-rays were done (Figures 2 and 3).



What is your diagnosis?

Diagnosis

The axial CT scan of the brain (Figure 1) shows dense calcification (brain stones) in the region of the basal ganglia and cerebral cortex.

Dense bones characteristic of osteopetrosis (Figures 2 and 3) are seen in the skeletal and skull X-rays. Investigation in this patient had documented metabolic acidosis suggesting a renal tubular defect.

The triad of cerebral calcification, renal tubular acidosis, and dense bone is seen in *carbonic anhydrase-II (CA-II) deficiency*.

Discussion

CA-II deficiency is an autosomal recessive disorder in which CA-II enzyme activity is lost. This enzyme activity is necessary for osteoclast-mediated bone resorption. Skeletal disease in CA-II deficiency resembles other forms of osteopetrosis and may in some cases be associated with multiple pathological fractures.

Mental subnormality of variable severity is present in over 90% of patients. Cerebral calcifications appear early by 2 to 5 years of age and are more pronounced in childhood.

In the kidney, this enzyme is necessary for bicarbonate reclamation. Patient with CA-II deficiency present with metabolic acidosis and high urine pH. Hyperchloraemic metabolic acidosis may be noted at birth and in some patients can be profound.

There is no established medical treatment for CA-II deficiency. Bone marrow transplantation from a human leukocyte antigen (HLA)-identical donor is an accepted treatment for the malignant form of osteopetrosis.

Author information: Suresh Prabhu, Senior Registrar; Jubbin J Jacob, Senior Registrar; Nihal Thomas, Consultant; Department of Endocrinology, Christian Medical College and Hospital, Vellore, Tamil Nadu, India

Correspondence: Jubbin Jagan Jacob, Senior Registrar, Department of Endocrinology, Christian Medical College, Vellore, Tamil Nadu, India 632004. Fax: +91 461 5203570; email: jubbin@india.com

References:

1. Whyte MP. Carbonic anhydrase II deficiency. Clin Orthop Relat Res. 1993;294:52–63.
2. Sly WS, Whyte MP, Sundaram V, et al. Carbonic anhydrase II deficiency in 12 families with the autosomal recessive syndrome of osteopetrosis with renal tubular acidosis and cerebral calcification. N Engl J Med. 1985;313:139–45.