



## **A case of acupuncture-induced pneumothorax**

Brian Kennedy, Lutz Beckert

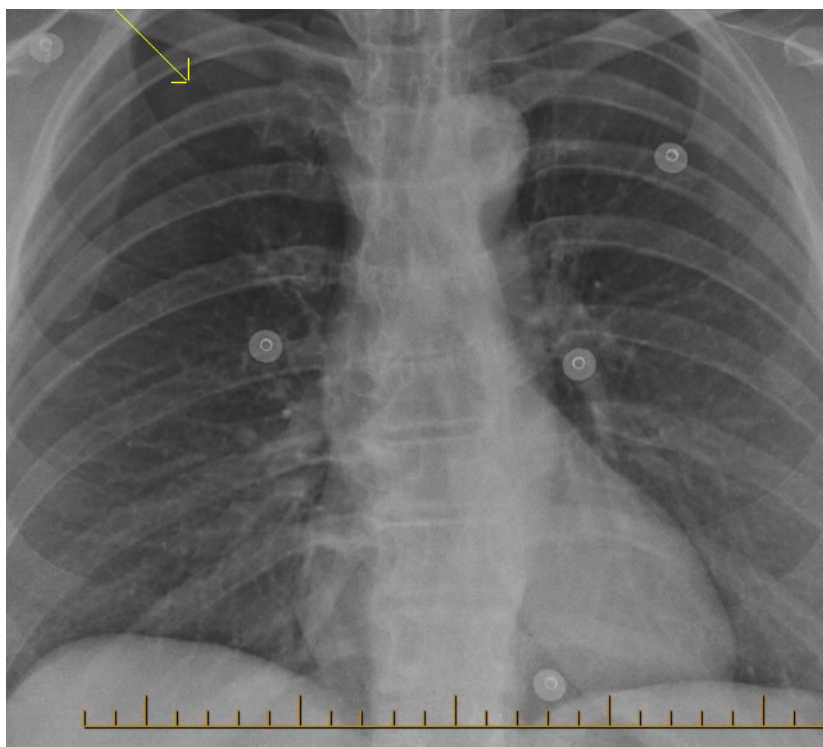
Mrs P, a 54-year-old woman, presented with chest pain and increasing shortness of breath. She suffers chronic left-sided musculoskeletal chest pain, for which she sought out acupuncture therapy.

It was during her second acupuncture session that she became acutely short of breath, following introduction of an acupuncture needle into the right side of her chest posteriorly. She developed “tightness” in the right apical area and associated chest pain. She immediately left the acupuncture clinic, returned home and called an ambulance when her shortness of breath and pain worsened.

On arrival to hospital she was dyspnoeic and distressed. She described her chest discomfort as being pleuritic in nature and exaggerated by movement. She has a 25-pack year smoking history, having stopped smoking about 10 years prior. On clinical examination, absent air entry was noted in the right hemithorax with hyper-resonance to percussion.

Her chest X-ray confirmed a moderate-sized right pneumothorax (Figure 1).

**Figure 1. Pneumothorax (lung border identified by arrow)**



Her pneumothorax was aspirated and 450 ml of air removed from the pleural space. Her symptoms improved following the drainage. However the following morning Mrs P was noted to be increasingly dyspnoeic after mobilising to the bathroom.

A repeat chest film demonstrated a recurrence of the right pneumothorax extending to the right base. She was treated with a 12-gauge chest drain into the fourth intercostal space anterior axillary line. Her lung reinflated, the chest drain was removed and she was discharged home the next morning.

## Discussion

Acupuncture is described as the insertion of one or more dry needles into the skin and subcutaneous tissue into acupuncture points. The term is derived from the Latin words “acus” meaning needle and “punctura” meaning penetration. Having originated in China over 2000 years ago, it remains a popular therapy for a variety of conditions today including chronic pain, nausea and vomiting, headache and hypertension. Its efficacy has proven difficult to ascertain.

A meta-analysis of randomised controlled trials of acupuncture for pain that included both sham acupuncture and no treatment arms found that the superiority of acupuncture over sham acupuncture, if real, appeared to be too small to be clinically important.<sup>1</sup>

Multiple models have been derived attempting to explain the perceived effects of acupuncture. Its most common use is in pain relief and this remains the most studied application. A popular theory is that of endorphin release. According to this theory, acupuncture stimulation is associated with neurotransmitter effects such as endorphin release at both the spinal and supraspinal levels.<sup>2,3</sup> It has been shown that opioid antagonists block the analgesic effects of acupuncture, supporting this theory.

Complications are infrequently observed with acupuncture treatment; however as with any form of needle use, adverse events can occur. These include transmission of diseases, needle fragments left in the body, nerve damage, pneumothorax, pneumoperitoneum, organ puncture, cardiac tamponade and osteomyelitis. Local complications include bleeding, contact dermatitis, infection, pain and paraesthesias.<sup>4,5</sup>

Despite the variety of listed complications and the occasional case reports, major adverse events are exceedingly rare and are usually associated with poorly trained unlicensed acupuncturists.<sup>6</sup> A prospective investigation in Germany of 97,733 patients constituting 760,000 treatment sessions reported that the two most frequently reported adverse events were needling pain (3.3 percent) and haematoma (3.2 percent).<sup>7</sup> Potentially serious adverse events included two cases of pneumothorax.

In conclusion, patients seeking acupuncture treatment should be directed to see only acupuncturists who are experienced and licensed. Despite the low risk of pneumothorax, all patients should be advised of the risk of pneumothorax when needles are being introduced into the thoracic region.

**Author information:** Brian Kennedy, Respiratory House Officer; Lutz Beckert, Respiratory Physician; Respiratory Medicine, Christchurch Hospital, Christchurch

**Correspondence:** Dr Lutz Beckert, Respiratory Medicine, PO Box 4345, Christchurch Hospital, Christchurch, New Zealand. Fax: +64 (0)3 3640914; email: [Lutz.Beckert@cdhb.govt.nz](mailto:Lutz.Beckert@cdhb.govt.nz)

**References:**

1. Madsen MV, Gotzsche PC, Hrobjartsson A. Acupuncture treatment for pain: systematic review of randomised clinical trials with acupuncture, placebo acupuncture, and no acupuncture groups. *BMJ* 2009;338:a3115.
2. Han JS, Terenius L. Neurochemical basis of acupuncture analgesia. *Annu Rev Pharmacol Toxicol* 1982; 22:193.
3. Andersson S, Lundeberg T. Acupuncture- from empiricism to science: functional background to acupuncture effects in pain and disease. *Med Hypotheses* 1995;45:271.
4. Lao L, Hamilton GR, Fu J, Berman BM. Is acupuncture safe? A systematic review of case reports. *Altern Ther Health Med* 2003; 9:72.
5. Ernst E, White AR. Prospective studies of the safety of acupuncture: a systematic review. *Am J Med* 2001;110:481.
6. Vickers A, Wilson P, Kleijnen J. Acupuncture. *Qual Saf Health Care* 2002;11:92.
7. Melchart, D, Weidenhammer, W, Streng A, et al. Prospective investigation of adverse effects of acupuncture in 97,733 patients. *Arch Intern Med* 2004; 164:104.