



MRI imaging of the inner ear for Meniere's disease

Jeremy Hornibrook, Mark Coates, Tony Goh, Philip Bird

Until now, imaging of the inner ear has been by computed tomography (CT) scanning which can delineate its bony borders, defects and congenital abnormalities. Because of their size, imaging of internal structures has not been possible. Therefore much inner ear pathology has been elucidated from post-mortem histology.

It is 70 years since temporal bone histology demonstrated that in Meniere's disease the fundamental abnormality is an excess of fluid in the endolymphatic compartment, called endolymphatic hydrops. The official definition of "definite" Meniere's disease is attacks of vertigo accompanied by documented fluctuating hearing and/or aural fullness in the affected ear, whereas "certain" Meniere's disease requires a post-mortem to prove the hydrops.¹

In animal models it had been shown, with long scanning times, that intratympanic delivery of gadolinium selectively enhances perilymph, delineating it from endolymph.² In humans, medical resonance imaging (MRI) inner ear studies have been limited by the spatial resolution of 1.5 Tesla scanners. Intratympanic gadolinium was shown to enter the human ear on 1.5 Tesla scanner in 2005.³

Newer scanners with greater magnetic strength and improved image sequencing have made ultrastructural detail achievable. On 3 Tesla scans, human endolymphatic hydrops has been clearly demonstrated.⁴⁻⁷ The dosage, timing of administration and safety have been established, and a grading system has been suggested.⁸

Patients

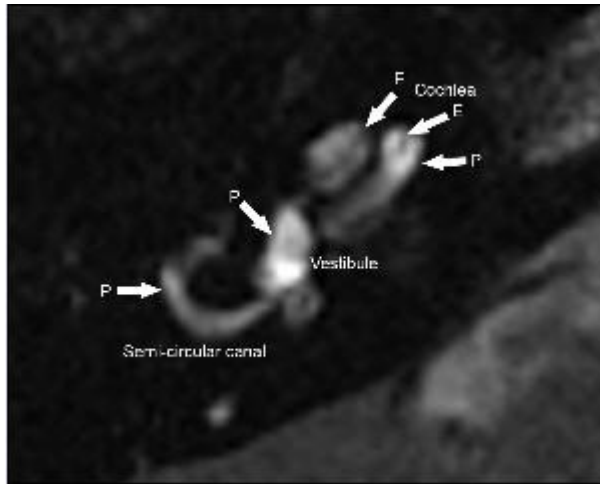
MRI inner ear scanning was conducted on two patients: (1) an 80-year-old male with vertigo attacks and mild right ear hearing loss, experiencing no aural symptoms and not fulfilling the AAOHNS criteria for Meniere's disease; and (2) a 46-year-old male with a 2-year ear history of vertigo attacks accompanied by progressive hearing loss, tinnitus and aural fullness in the right ear fulfilling the criteria for Meniere's disease.

Twenty-four hours before the scan, multihance gadolinium 1.6 ml in 10 ml saline was introduced to the right middle ear through a small myringotomy (and replenished 4 to 5 times, a total of 1.0–1.5 ml over 45 minutes with the patient lying to the opposite side).

Images were obtained on a 3 Tesla Magnet (General Electric HDX). Two inversion recovery sequences were obtained with inversion times of T1 1000 (endolymph) and 2500 (perilymph) in addition to routine 3D Fiesta imaging of the inner ear/IAMs.

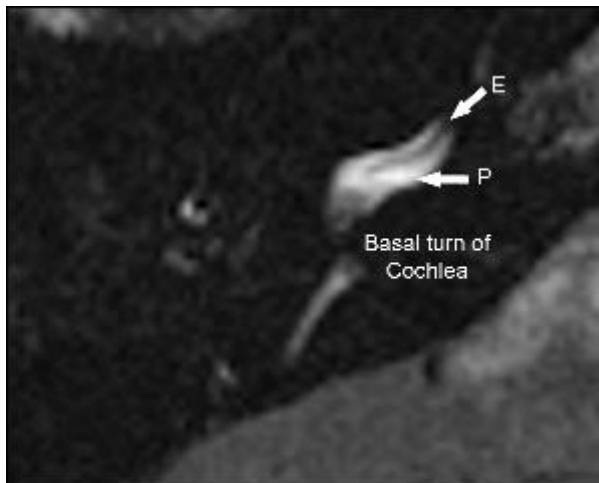
Patient 1. Normal inner ear: no hydrops

Figure 1. Perilymph sequence. The cochlea, vestibule and one semicircular canal are labelled.



P=perilymph, E=endolymph.

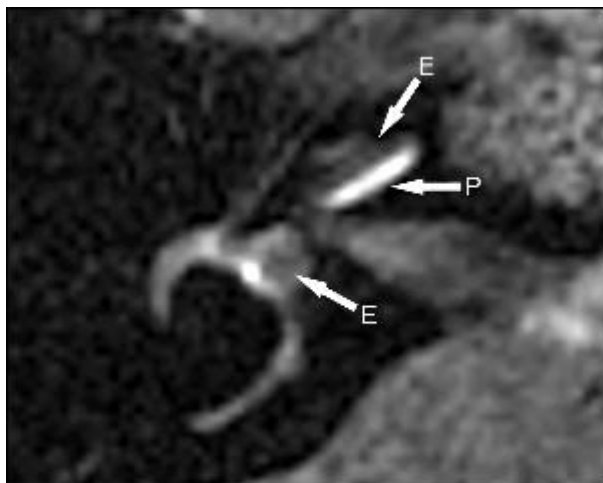
Figure 2. Perilymph sequence. Basal turn of the cochlea, with normal endolymphatic compartment; no hydrops.



P=perilymph, E=endolymph.

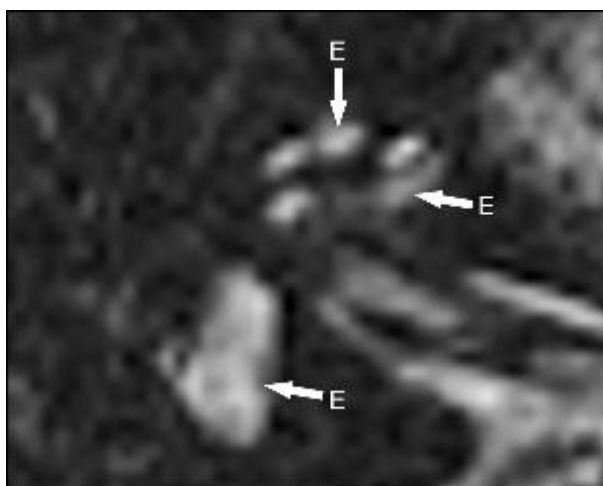
Patient 2. Meniere's disease: significant hydrops

Figure 3. Perilymph sequence. Significant enlargement [33–50%] of the endolymphatic compartment in the cochlea; in the vestibule and semicircular canal endolymphatic hydrops [>50%] has displaced almost all perilymph.



P=perilymph, E=endolymph.

Figure 4. Endolymph sequence. Enlargement of the endolymphatic compartment in the cochlea; endolymph fills the vestibule.



E=endolymph.

Discussion

In these two subjects, MRI inner ear scanning was normal in Patient 1 and clearly showed endolymphatic hydrops in Patient 2 with a history fulfilling the AAOHNS criteria for a diagnosis of “definite” Meniere’s disease.¹

The recently proposed hydrops grading system⁸ is simple: none, mild, significant. In the vestibule an endolymph/perilymph ratio of one-third=none; one-third to one-half=mild; and >50%=significant. In the cochlea, no Resisner's membrane displacement=none; Resisner's membrane displacement with the area of the endolymphatic compartment not exceeding the area of the scala vestibuli (perilymph)=mild; the endolymphatic space exceeds the area of the scala vestibuli (perilymph)=significant.

Early human studies established that intratympanically administered gadolinium enhances cochlear perilymph within 4 hours⁶ and the perilymph in all areas by 24 hours.³ In three patients scanned at 6 days the gadolinium and had almost disappeared.³ In animal studies a 8-fold dilution of gadolinium had no adverse affects on the stria vascularis⁹, and there have been no reports of it causing hearing loss or aggravating tinnitus.

In Japan, Nakashima et al¹⁰ have used MRI imaging to study 73 patients with inner ear diseases including Meniere's disease, idiopathic sudden sensorineural hearing loss, and fluctuating hearing loss without vertigo. They used 3D-real IRI (a 3-dimensional technique) MRI which gives clearer visualisation of the perilymph space than the 2-dimensional technique used in New Zealand.

MRI scanning of the inner ear is an exciting new development in the diagnosis of inner ear conditions. Correlation of symptoms with imaging should significantly contribute to the understanding of inner ear diseases. For example, recurrent non-positional attacks of vertigo similar to Meniere's disease without hearing loss may be due to endolymphatic hydrops, or have an entirely different pathology.

Conversely, fluctuating hearing loss, tinnitus and aural fullness often occur without vertigo. Do these people have endolymphatic hydrops confined to the cochlea? Although patients with unilateral inner ear symptoms usually receive MRI scanning to exclude vestibular schwannoma/acoustic neuroma, both this and intratympanic gadolinium are mildly invasive.

Rigorous clinical research will be required to delineate the role of this new technology in the management of Meniere's disease and other inner ear conditions.

Author information: Jeremy Hornibrook and Philip Bird, Otolaryngologists, Christchurch Hospital, Christchurch; Mark Coates and Tony Goh, Radiologists, Christchurch Hospital and Christchurch Radiology Group, Christchurch; Philip Bird, Senior Lecturer, Department of Surgery, University of Otago, Christchurch

Correspondence: Jeremy Hornibrook, Department of Otolaryngology-Head and Neck Surgery and Audiology, 2 Riccarton Avenue, Christchurch 8011, New Zealand. Fax: +64 (0)3 3642073; email: jeremy@jhornibrook.com

References:

1. Committee on Hearing and Equilibrium. Guidelines for the diagnosis and evaluation of therapy in Meniere's disease. *Otolaryngol Head Neck Surg* 1995;113:181-5.
2. Niyazov DM, Andrews JC, Stretlioff D, et al. Diagnosis of endolymphatic hydrops in vivo with magnetic resonance imaging. *Otol Neurotol* 2001;22:813-7.
3. Zou J, Pytko I, Bjelke B, et al. Communication between the perilymphatic scale and spiral ligament visualized by in vivo MRI. *Audiol Neurotol* 2005;10:145-52

4. Nakashima T, Naganawa S, Sugiura M, et al. Visualization of endolymphatic hydrops in patients with Meniere's disease. *Laryngoscope* 2007;117:415-20.
5. Naganawa S, Sugiura M, Kawamura M, et al. Imaging of endolymphatic and perilymphatic fluid at 3T after intratympanic administration of gadolinium- diethylene-triamine pentaacetic acid. *AJNR* 2008;April:724-6
6. Carfrae MJ, Holtzman A, Parnes SM, et al. 3 Tesla delayed contrast magnetic resonance imaging evaluation of Meniere's disease. *Laryngoscope* 2008;118:501-5.
7. Naganawa S, Nakashima T. Cutting edge of inner ear MRI. *Acta Oto-Laryngologica* 2009;129:15-21.
8. Nakashima T, Naganawa S, Pyykkö I, et al. Grading of endolymphatic hydrops using magnetic resonance imaging. *Acta Oto-Laryngologica* 2009;129:5-8.
9. Kakigi A, Nishimura M, Takeda T, et al. Effects of gadolinium injected into the middle ear on the stria vascularis. *Acta Otolaryngol* 2008;128:841-5.
10. Nakashima T, Naganawa S, Katayama N. Clinical significance of endolymphatic imaging after intratympanic gadolinium injection. *Acta Oto-Laryngologica* 2009;129:9-14.